

Diffusion Tensor MRI study of the spinal cord in patients with Multiple Sclerosis

J. von Meyenburg¹, B. Wilm², A. Weck³, E. Gallus¹, E. Schätzle¹, P. Boesiger², N. Goebels³, and S. S. Kollias¹

¹Institute of Neuroradiology, University Hospital Zürich, Zürich, Switzerland, ²Institute for Biomedical Engineering, University & ETH Zürich, Zürich, Switzerland,

³Department of Neurology, University Hospital Zürich, Zürich, Switzerland

Introduction

Anatomical MR contrasts (such as T₁ and T₂) fail to identify occult lesions and diffuse demyelination which are known to occur in multiple sclerosis (MS). Diffusion tensor imaging (DTI) can potentially discern axonal loss in white-matter tissue and serve as a marker for loss of tissue integrity (demyelination, axonal degeneration) [1,2].

Poor image quality and the limited resolution in spinal cord DWI has so far impeded focal evaluation of spinal cord tissue i.e. the differentiation between grey and white matter. Furthermore, adequate image quality was achievable only at the cervical level of the spinal cord. Recent improvements in MR pulse sequence design have overcome these problems, thereby providing a new instrument for the assessment of multiple sclerosis. We tested the newly available technique in a comprehensive clinical MS study and measured diffusivity values of the spinal cord at three levels.

Methods

Imaging was performed on a 3 T Philips Achieva (Philips Healthcare, Best, the Netherlands) using a dedicated spine coil. DTI data of 18 volunteers and 41 patients with relapsing remitting MS (RRMS), secondary progressive MS (SPMS) or primary progressive MS (PPMS) (Table 1) were acquired at cervical (~C5) and thoracic level (~T5) as well as at the lumbar enlargement of the spinal cord. In each region 6 transverse slices were acquired using an outer volume suppressed reduced field of view single-shot EPI sequence [3,4] (NEX = 6/12 for b = 0/b = 750 s/mm², acquisition matrix = 176x44, FOV = 120x30 mm², z=5mm, TR = 4000 ms, TE = 49 ms, 60% partial-Fourier acquisition). After subsequent image co-registration fractional anisotropy (FA) and apparent diffusion coefficient (ADC) maps were calculated. Diffusivity values were evaluated in the posterior white matter (PWM) (Fig. A). Only normal appearing spinal cord tissue, i.e. spinal cord tissue without T₂-hyperintense lesions, was evaluated. ROI sizes were kept constant for all evaluated subjects.

Table 1	Volunteers	RR-MS	SP-MS	PP-MS	all patients
Number	18	15	14	12	41
Male/female	11/7	5/10	9/5	8/4	22/19
Mean age ± SD years (range)	51.83 ± 16.65 (22-83)	43.20 ± 8.87 (29-60)	54.43 ± 10.50 (42-74)	57 ± 14.54 (32-75)	51.54 ± 12.62 (29-75)
Disease duration±SD years (range)		8.06 ± 5.28 (2-17)	18.14 ± 11.60 (4-43)	11.1 ± 5.16 (4-18)	12.43 ± 9.34 (2-42)

Results

Mean fractional anisotropy in the posterior white matter (PWM) was highest in the healthy subjects and lowest in the PPMS group (Fig. B). The mean apparent diffusion coefficient was lowest in volunteers and highest in the RRMS group, respectively (Fig. C). In the patient groups (RR-MS, SP-MS and PP-MS) the decrease of FA was most prominent on cervical level and visible on thoracic level as compared to healthy volunteers (Fig. D). At the lumbar enlargement similar FA values were observed in patients and healthy subjects.

Discussion

Correlation between diffusion anisotropy and axonal density [2] in spinal MS lesions has been observed by comparing MRI images and neuropathological findings. Based on these observations our results suggest that axonal degeneration is most prominent in the PPMS group as FA in the PWM was lowest in these patients. On the other hand highest ADC values were seen in the RRMS group which might indicate that the degree of myelin loss in the RRMS patients is strongest [2]. The fact that the PWM FA difference between patients and the control group was highest at cervical level and decreasing when moving caudally (Fig. D), might reflect a decreasing loss of tissue integrity in a cranio-caudal sense. This goes along with an observed decrease of T₂-hyperintense lesions when moving caudally in the spinal cord [5].

Conclusion

Diffusivity values measured in normal appearing spinal cord tissue are presented in a comprehensive clinical MS study. An interesting finding was the difference in diffusivity behaviour between the patient groups, probably related to different neuropathological changes amongst MS types. Furthermore the diffusivity values suggest that the degree of inflammation causing axonal loss is strongest on cervical level.

Correlation between anatomical analysis by the described diffusion tensor MR methodology in further regions of the spinal cord in white and grey matter with electrophysiological (motor evoked potentials, somatosensory evoked potentials) and clinical tests are ongoing.

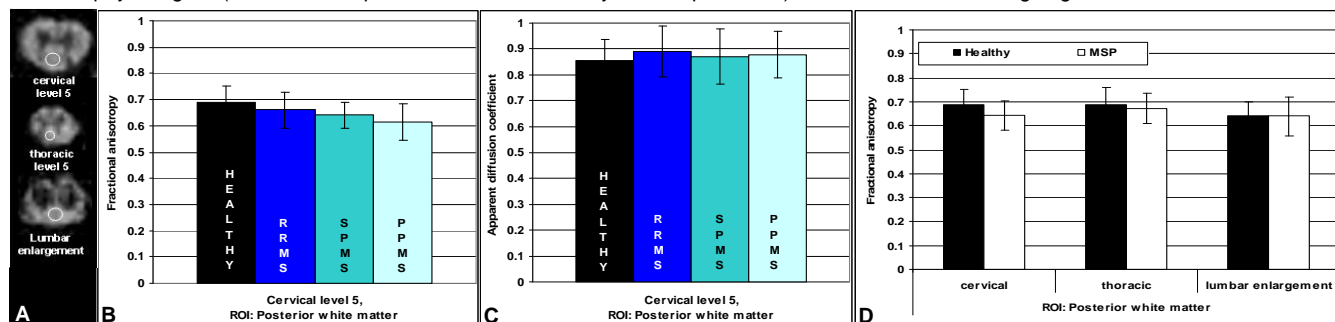


Fig. A: Transversal FA images of the spinal cord at the three levels. Circles = regions of Interest. **Fig. D:** MSP = MS patients

[1] Ohgiya Y. et al, Eur Radiol. 2007 Oct;17(10):2499-504

[2] Mottershead J.P. et al., J Neurol. 2003 Nov;250(11):1293-301

[3] Wilm B.J. et al., NMR Biomed. 2008 Aug 26.

[4] Wilm B.J. et al, Magn Reson Med. 2007 Mar;57(3):625-30

[5] Tartaglino L.M. et al, Radiology. 1995 Jun;195(3):725-32

This study was financially supported by the Swiss Multiple Sclerosis Society.