

Comparison of 3D Stress Cardiac Magnetic Resonance Perfusion Imaging and Invasive Fractional Flow Reserve Measurements for the Detection of Coronary Artery Disease

R. Manka^{1,2}, C. Jahnke³, P. Boesiger¹, T. Lüscher², I. Paetsch³, and S. Kozerke¹

¹Institute for Biomedical Engineering University and ETH Zürich, Zürich, Switzerland, ²Cardiology, Unispital Zürich, Zürich, Switzerland, ³Cardiology, University Hospital RWTH Aachen, Aachen, Germany

Introduction:

First-pass stress perfusion CMR is highly accurate for the detection of coronary artery disease (CAD) and crucial for the assessment of myocardial ischemia (1). However, established two-dimensional multi-slice acquisitions have limited spatial coverage of the heart and therefore do not offer the possibility to quantify the individual ischemic burden. The need for whole ventricular coverage was demonstrated by patient studies performed using nuclear imaging (2). In accordance, the transition from two- to three-dimensional (3D) stress CMR perfusion imaging techniques has been a recent focus of development (3,4) and it has been hypothesized that 3D perfusion imaging could enable direct measurement of the ischemic burden.

The purpose of the present study was to evaluate 3D whole heart stress CMR perfusion imaging versus invasive fractional flow reserve (FFR) measurements taken during invasive X-ray angiography for the detection of CAD.

Methods:

Sixteen patients (mean age 64 ± 12 years, 2 female) with known or suspected CAD awaiting invasive X-ray angiography underwent a 1.5 Tesla CMR examination using 10-fold accelerated 3D k-t PCA (4) (TR/TE/flip angle: 1.8ms/0.7ms/15°, saturation prepulse delay: 150 ms, partial Fourier acquisition, 16 slices, voxel size: $2.3 \times 2.3 \times 5.0$ mm³). Perfusion scans were obtained under adenosine stress (140 µg/kg/min for 6 min; 0.1mmol/kg Gd-DTPA) and at rest. FFR was recorded in all patent epicardial coronary arteries (significant stenosis <0.75 and ≤ 0.80). For visual analysis, 3D CMR perfusion scans were classified as pathologic if ≥ 1 segment showed an inducible perfusion deficit ($>25\%$ transmural). Overall image quality of stress and rest 3D CMR perfusion scans was graded on a scale between 1 and 4 (1= nondiagnostic, 2= poor, 3= good, 4= excellent).

Results:

All studies were completed successfully. A data set of a patient with hypoperfusion in the inferior wall along with the corresponding X-ray angiogram is shown in Figure 1. Analysis of 3D CMR perfusion resulted in a sensitivity and specificity of 88% and 88% for a FFR cut off ≤ 0.80 and 86% and 78% for a FFR cut off <0.75 . The mean visual score of 3D perfusion imaging was 3.6 ± 0.6 during adenosine stress and 3.8 ± 0.5 at rest. No study was graded as non-diagnostic (Figure 2; $p=ns$).

Discussion:

The 3D CMR stress perfusion protocol was well accepted by all patients and the data showed high image quality and high diagnostic accuracy for the detection of significant CAD compared with FFR measurements. Respiratory drifts during the k-t PCA perfusion scans did not significantly affect image quality in contrast to previous approaches using the k-t SENSE reconstruction technique (5).

References:

- (1) Schwitzer J et al. Eur Heart J. 2008 Feb;29(4):480-9.
- (2) Shaw LJ et al. Circulation 2008;117:1283–1291.
- (3) Shin T et al. J Cardiovasc Magn Reson. 2008 Dec 11.
- (4) Vitanis V et al. Magn Reson Med. 2010 Oct 6.
- (5) Plein S et al. Eur Heart J. 2008 Sep;29(17):2148-55.

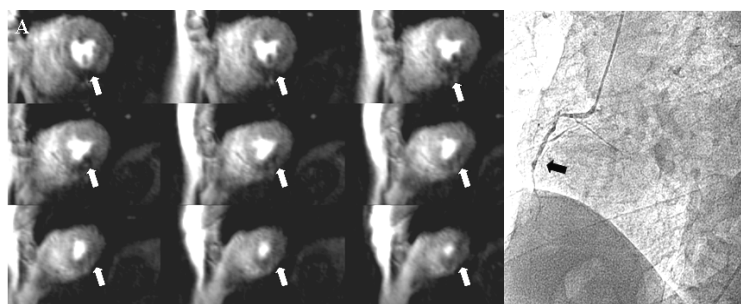


Figure 1: Patient example with nine out of sixteen consecutive slices of 3D CMR stress perfusion images; basal (top left) to apical (bottom right). (A) Inferior hypoperfusion from apical to basal slices (white arrow). (B) Invasive X-ray angiography confirming an occluded right coronary artery (black arrow).

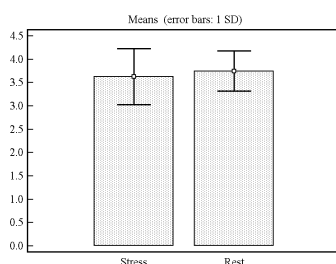


Figure 2: Image quality scores for stress and rest 3D CMR perfusion imaging.