

## Multicenter Evaluation of Dynamic Three-dimensional Whole-heart Myocardial Perfusion Imaging at 3.0 Tesla for the Detection of Coronary Artery Disease Defined by Fractional Flow Reserve

Robert Manka<sup>1,2</sup>, Rolf Gebker<sup>3</sup>, Lukas Wissmann<sup>1</sup>, Roy Jogiya<sup>4</sup>, Manish Motawani<sup>5</sup>, Michael Frick<sup>6</sup>, Sebastian Reinartz<sup>6</sup>, Bernhard Schnackenburg<sup>7</sup>, Eike Nagel<sup>1</sup>, Sven Plein<sup>5</sup>, and Sebastian Kozerke<sup>1</sup>

<sup>1</sup>University and ETH Zurich, Zurich, Switzerland, <sup>2</sup>University Hospital Zurich, Zurich, Switzerland, <sup>3</sup>German Heart Institute Berlin, Berlin, Germany, <sup>4</sup>King's College London, London, United Kingdom, <sup>5</sup>University of Leeds, Leeds, United Kingdom, <sup>6</sup>University Hospital RWTH Aachen, Aachen, Germany, <sup>7</sup>Philips Healthcare, Clinical Sciences, Berlin, Germany

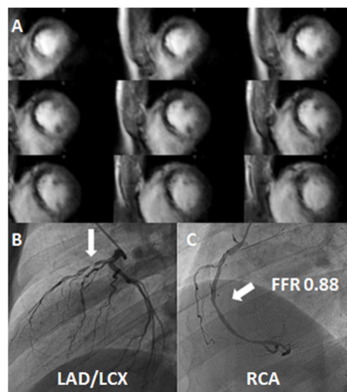
**Introduction:** Cardiac magnetic resonance (CMR) perfusion imaging yields high diagnostic accuracy for the detection of coronary artery disease (CAD) [1]. However, standard 2D multi-slice CMR perfusion techniques only provide limited coverage and hence prohibit computation of myocardial ischemic burden. Recently, two single-center 3D CMR perfusion studies have proven highly diagnostic for the detection of CAD relative to quantitative coronary angiography (QCA) [2] and fractional flow reserve (FFR) [3]. The aim of our prospective multicenter study is to assess the diagnostic performance of 3D CMR perfusion imaging in comparison with FFR.

**Methods:** Five centers across Europe have been enrolled to acquire 3D CMR perfusion and FFR data in a total of 150 patients with suspected CAD. CMR 3D perfusion imaging employs 10-fold accelerated k-t PCA [4] providing whole heart coverage with a spatial resolution of 2.3x2.3x5 mm<sup>3</sup> on 3.0T systems (Philips Healthcare, Best, The Netherlands). Perfusion scans were obtained under adenosine stress (140 µg/kg/min for 6 min; 0.075mmol/kg gadobutrol; Gadovist, Bayer Schering Pharma, Berlin, Germany) and at rest. FFR was recorded in all patent epicardial coronary arteries (significant stenosis <0.75). For visual analysis, 3D CMR perfusion scans were classified as pathologic if ≥1 segment showed an inducible perfusion deficit with >25% transmural. Overall image quality of stress and rest 3D CMR perfusion scans was graded on a scale between 1 and 4 (1= non-diagnostic, 2= poor, 3= good, 4= excellent). All CMR perfusion analyses were performed in central core-lab, blinded to all clinical data.

**Results:** Here we report preliminary results obtained in the first 48 patients (mean age 63±11 years, 14 female). CAD prevalence as defined by FFR (<0.75) was 35% (17 of 48 patients). 3D CMR perfusion resulted in a sensitivity and specificity of 88% and 84%, respectively. The mean visual score of 3D perfusion imaging was 3.5 ± 0.6 during adenosine stress and 3.6 ± 0.5 at rest (p= 0.08). No study was graded as non-diagnostic. Figure 1 shows a representative patient example with extensive inducible ischemia during stress perfusion in the anterior and septal wall (2A) caused by a subtotal occlusion of the left anterior descending artery (2B). The right coronary artery stenosis (2C) was hemodynamically not relevant (FFR 0.88).

**Conclusion:** In this preliminary assessment of a sub cohort of our multicenter study 3D CMR perfusion imaging proved highly diagnostic for the detection of functionally significant CAD as defined by FFR. Analysis of the remaining data is required to fully conclude on the finding presented here.

**References:** [1] Greenwood J et al., Lancet (2012). [2] Manka R et al., JACC (2011). [3] Jogiya R et al., JACC (2012), [4] Vitanis V et al. MRM (2011)



**Figure 1:** Figure 2 shows a representative patient example with extensive inducible ischemia during stress perfusion in the anterior and septal wall (2A) caused by a subtotal occlusion of the left anterior descending artery (white arrow, 2B). Right coronary artery stenosis (white arrow, 2C) was hemodynamically not relevant (FFR 0.88).