

# Dynamic MRI Encodes Differential Contraction of Extraocular Muscle Segments in Healthy Subjects

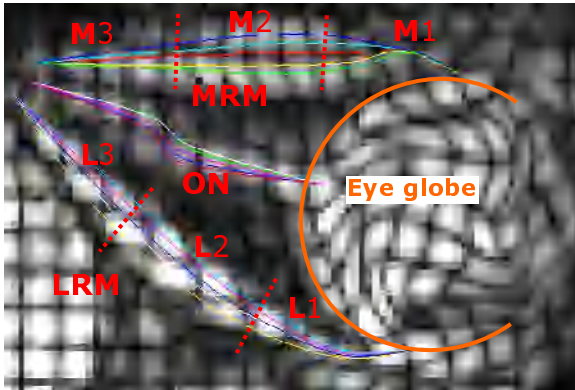
M. Piccirelli<sup>1,2</sup>, R. Luechinger<sup>1</sup>, O. Bergamin<sup>2</sup>, A. K. Rutz<sup>1</sup>, and P. Boesiger<sup>1</sup>

<sup>1</sup>Inst. for Biomedical Engineering, University and ETH Zürich, Zürich, Switzerland, <sup>2</sup>Dept. of Ophthalmology, University Hospital, Zürich, Switzerland

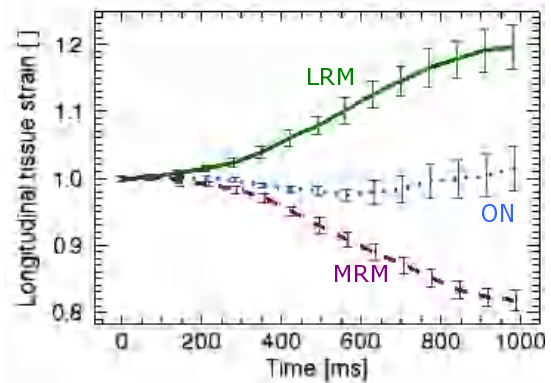
**Introduction:** Nowadays, static MRI and CT are essential clinical tools for detecting mechanical disorders of the orbit [1]. In complex cases, however, there is an additional need to better understand the dynamics of ocular movements. A lack of movement may be due to contraction or relaxation deficits of the six extraocular muscles or due to rigid surrounding orbital connective tissue. The pattern of the lack of movement within extraocular muscles has not been understood yet [2]. This study presents a scanning method that provides motion encoded high-resolution MR images of the extraocular muscles and the optic nerve (Complementary SPAtial Modulation of Magnetization – CSPAMM [3]). The strains along the optic nerve and the horizontal rectus muscles were analyzed in detail.

**Methods:** For reproducible and accurate eye alignment during image acquisition, seven healthy subjects gazed at a horizontal sinusoidal moving target (2s period, peak velocity 64°/s, amplitude  $\pm 20^\circ$ ), presented with a typical fMRI setup (software: “Presentation” and digital projector). A microscopy coil (47mm diameter) at 1.5T was used on one orbit to acquire 2D CSPAMM images (112x51 scan-matrix, 256x256 recon.-matrix, scantime 4min., 15 time phases of 70ms, resolution: 0.5x0.5x4 mm<sup>3</sup>, EPI factor: 5, tag-line distance: 3mm). The optic nerve and the horizontal rectus muscles were tracked (using peak-combination HARP [4, 5]), each with five contours of about equal length (Figure 1). The averages of the five contours were calculated. For intersubjects comparison: the muscles were first length normalized and then divided into three parts of equal size.

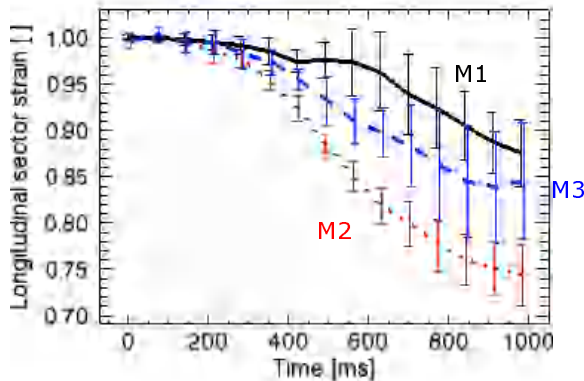
**Results:** The sinusoidal movement of the contracting and relaxing horizontal rectus muscles, and the non-contracting optic nerve were reliably tracked and clearly separated from each other (Figure 2). The muscle belly could be sorted from the muscle origin (orbital apex) and insertion (on the eye sclera), in each subject. The variability among the seven subjects was small (Figure 3 and 4).



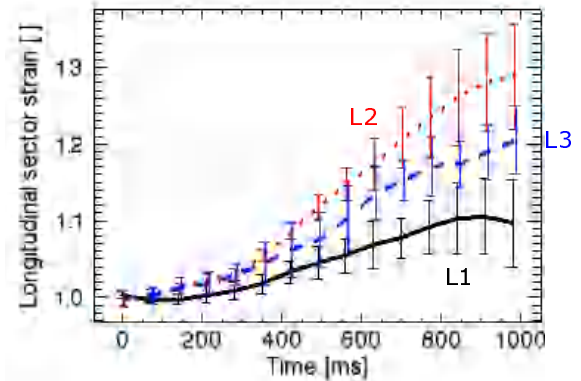
**Figure 1:** CSPAMM image with contours definition on the 10th time phase (out of the 15). Five contours served to track the whole thickness of the two muscles and the optic nerve. Top: medial rectus muscle (MRM). Middle: optic nerve (ON). Bottom: lateral rectus muscle (LRM). The muscles were divided into three parts of equal length (L1, L2, L3 resp. M1, M2, M3)



**Figure 2:** Subjects averaged strain, in function of time, for the LRM (relaxing; in green), the ON (in blue), and the MRM (contracting; in violet). The tissues can be separated from each other. The projection of the ON 3D deformation on the image plan is depicted. (Error bars sizes: two standard deviations.)



**Figure 3:** Averaged strain of 7 subjects in function of time, for the contracting MRM: eye ball sector (in black), his belly (in red), and the orbital apex sector (in blue). The three sectors can be separated from each other. (Error bars sizes: two standard deviations.)



**Figure 4:** Averaged strain of 7 subjects in function of time, for the relaxing LRM: eye ball sector (in black), his belly (in red), and the orbital apex sector (in blue). The three sectors can be separated from each other. (Error bars sizes: two standard deviations.)

**Conclusion:** The MRI motion encoded technique used in this study enabled to resolve the differential contraction of extraocular muscle segments in healthy subjects. Further studies plan to investigate the ability of this technique to differentiate pathologic from the physiologic muscle contraction pattern. Then, the loss of functionality may be assigned to certain extraocular muscle segments.

## References:

1. Demer JL, et al. A 12-Year, prospective study of extraocular muscle imaging in complex strabismus. J AAPOS 2002; 6(6): 331-47
2. Miller JM, et al. Stability of gold bead tissue markers. JOV 2006; 6: 616-624
3. Fischer SE, et al. Improved myocardial tagging contrast. MRM 1993; 30(2): 191-200.
4. Osman NF, et al. Cardiac Motion Tracking Using CINE Harmonic Phase (HARP) Magnetic Resonance Imaging. MRM 1999; 42: 1048-1060
5. Ryf S, et al. Peak-Combination HARP: A Method to Correct for Phase Errors in HARP. JMRI 2004; 20: 874-880